

Successful Medical Management of Severe Bilateral Emphysematous Pyelonephritis: Case Studies

Raiz A. Misgar, Arshad I. Wani, Mir I. Bashir, Nazir Ahmad Pala, Idrees Mubarak, Muzamil Lateef, and Bashir A. Laway

Infections remain a major cause of morbidity and mortality in patients with diabetes in developing countries (1). Many infections are more common in patients with diabetes, and some occur almost exclusively in these patients. Emphysematous pyelonephritis (EPN) is an uncommon infection of the kidney characterized by production of gas within the renal parenchyma, collecting system, or perinephric tissue. Mostly confined to patients with diabetes (>90% of all cases occur in patients with diabetes), this life-threatening infection carries a mortality rate as high as 80% (2,3).

The first case of EPN was reported by Kelly and MacCullum in 1898 (4). The term "emphysematous pyelonephritis" was recommended by Schultz and Klorfein (5) because of its emphasis on the relationship between the gas formation and the nature of the infectious process.

Bilateral EPN (10%) is a rare phenomenon (6). The management of EPN has traditionally been aggressive, and nephrectomy is considered the treatment of choice (7). Such an approach in bilateral EPN would entail life long renal replacement therapy. Successful nonsurgical management of bilateral EPN has been previously reported (8). This article describes two additional cases in which bilateral EPN was successfully managed medically.

Presentation 1

M.K. was a 20-year-old woman who had had type 1 diabetes for 12 years,

complicated by azotemic nephropathy, peripheral neuropathy, and non-proliferative diabetic retinopathy. She had been contracting recurrent urinary tract infections for the past 2 years and presented with a high-grade fever (temperature 102°F), bilateral flank pain, and repeated vomiting for 1 week. Oral ciprofloxacin prescribed by her general practitioner had provided no relief.

Clinical examination revealed a distressed, apparently ill patient with tachycardia, tachypnea, pallor, dehydration, hypotension (blood pressure 90/60 mmHg), and tender renal angles. The patient's kidneys were not palpable. Laboratory investigations revealed anemia, neutrophilic leukocytosis, azotemia, and heavy pyuria (Table 1). She had mild diabetic ketoacidosis (DKA; blood glucose 637 mg/dL, serum pH 7.30, HCO₃ 12.7 mEq/L, and moderate

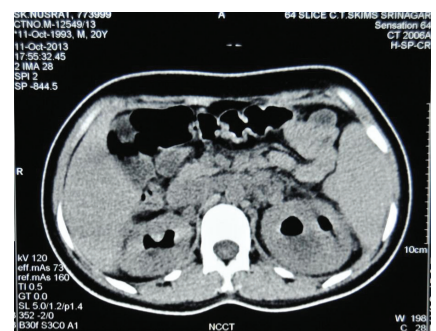


FIGURE 1. Noncontrast computed tomography of patient M.K.'s abdomen on day 1 revealed diffusely enlarged kidneys and extensive gas in the kidneys bilaterally, indicative of bilateral EPN (class 4 EPN).

Department of Endocrinology, Sher-i-Kashmir Institute of Medical Sciences, Srinagar, Kashmir, India

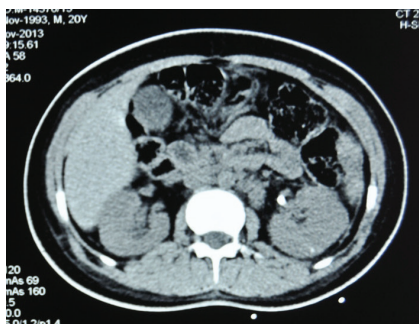
Corresponding author: Raiz A. Misgar, dreyaz07@rediffmail.com

DOI: 10.2337/diaclin.33.2.76

©2015 by the American Diabetes Association. Readers may use this article as long as the work is properly cited, the use is educational and not for profit, and the work is not altered. See <http://creativecommons.org/licenses/by-nc-nd/3.0> for details.

TABLE 1. Laboratory Parameters

Parameter	Case 1				Case 2			
	Day 1	Day 4	Day 14	Day 21	Day 1	Day 4	Day 14	Day 21
Hemoglobin (g/dL)	8.3	8.9	9.3	10.7	9.0	9.3	10	11.2
Total leukocyte count (mm ³)	10,730	10,430	9,200	8,160	16,200	13,500	12,300	7,600
Platelet count (mm ³)	160,000	170,000	190,000	371,000	33,000	38,000	140,000	381,000
Creatinine (mg/dL)	4.7	4.2	3.6	2.1	3.0	3.0	2.6	2.0
Glucose (mg/dL)	637	234	170	130	710	298	193	145
Serum pH	7.30	7.36	7.38	7.42	7.35	7.39	7.39	7.4
HCO ₃ ⁻ (mEq/L)	12.7	15.3	20.2	22.2	17	19	20	23.5
Urine pus cells	Full field	Full field	20–25	5–6	Full field	40–46	10–15	2–3



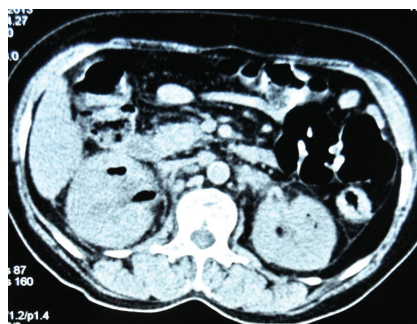■ **FIGURE 2.** Disappearance of gas in M.K.'s kidneys 4 weeks after initiation of treatment.

ketonuria). Her A1C was 10.2%. A noncontrast computed tomography (NCCT) of the abdomen performed on day 1 revealed bilateral EPN (class 4 EPN) (Figure 1). *Escherichia coli* sensitive to imipenem and levofloxacin was grown from her urine.

Treatment of DKA with intravenous fluids, insulin infusion, and parenteral antimicrobial treatment with imipenem and levofloxacin heralded clinical improvement, marked by subsidence of fever, vomiting, and abdominal pain, from day 3. Ultrasonography of the abdomen performed on day 14 revealed minimal air foci in the kidneys. Continued antibiotic treatment during the next 2 weeks led to complete clinical defervescence. An NCCT of the abdomen obtained 4 weeks after initiation of treatment revealed complete resolution of EPN (Figure 2).

Presentation 2

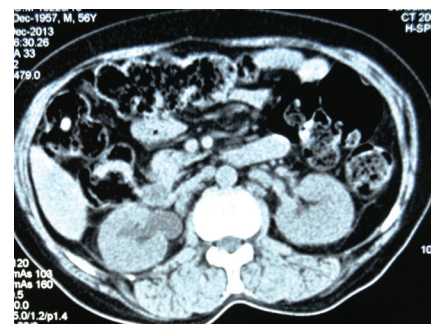
C.B., a 56-year-old woman with type



■ **FIGURE 3.** Noncontrast computed tomography of patient C.B.'s abdomen on day 1 revealed diffusely enlarged kidneys and extensive gas in the kidneys bilaterally, indicative of bilateral EPN (class 4 EPN).

2 diabetes diagnosed at the age of 36 years and complicated by azotemic nephropathy, peripheral neuropathy, and nonproliferative diabetic retinopathy presented with high-grade fever (temperature 103°F), chills, dysuria, and recurrent emesis of 10 days' duration. Oral antibiotic treatment for 5 days before presentation had afforded no relief.

On clinical examination, she appeared ill, with tachycardia, dehydration, fever, and tender renal angles. Her admission blood glucose was 710 mg/dL, and her A1C was 7.3%. She had neutrophilic leukocytosis, thrombocytopenia, azotemia, normal serum pH and electrolytes, no ketonuria, and full-field leucocyturia (Table 1). Her urine grew *E. coli*. Computed tomography revealed bilateral EPN (Figure 3).



■ **FIGURE 4.** Disappearance of gas in C.B.'s kidneys 6 weeks after initiation of treatment.

She was managed with fluid resuscitation, insulin infusion, and intravenous antibiotics (imipenem and amikacin). Clinical defervescence began after 4–5 days of treatment and culminated in complete recovery during the next 2 weeks. An NCCT of the abdomen obtained 6 weeks after treatment revealed complete resolution of EPN (Figure 4).

Questions

1. When should EPN be suspected in a patient with diabetes?
2. Is medical management alone sufficient for bilateral EPN?
3. What factors predict survival in patients with EPN?

Commentary

The possibility of EPN should always be considered in patients with diabetes who present with even seemingly routine, uncomplicated pyelonephritis. It becomes a serious consideration when fever continues after 3–4 days

of treatment of what is thought to be uncomplicated pyelonephritis. In such cases, an early NCCT scan can reveal the diagnosis, reduce delays in treatment, and limit morbidity and mortality.

Factors that may be involved in the pathogenesis of EPN include high blood glucose, glucose-fermenting bacteria (gas-forming coli-form bacteria), impaired vascular supply with decreased tissue perfusion, and impaired immune response (9). The most common causative bacterial pathogens are *E. coli* (68%) and *Klebsiella pneumoniae* (29%) (10). Other organisms include *Proteus mirabilis*, *Pseudomonas*, *Enterobacter*, *Candida*, and, rarely, *Clostridia* species. The classification scheme proposed by Huang and Tseng (11) is based on NCCT appearance: class 1, gas in the collecting system; class 2, gas in renal parenchyma without extension into extra renal space; class 3A, extension of gas to perinephric space; class 3B, extension of gas to perinephric space; and class 4, bilateral EPN or single-kidney EPN. Both of the cases described here involved class 4 EPN.

Traditionally, early nephrectomy has been considered the treatment of choice (7). This approach in bilateral disease will leave the patient with a lifelong need for renal replacement therapy. With the availability of better imaging modalities, potent antibiotics, and image-guided drainage, an initial conservative approach is appealing (8). In 1996, Chen et al. (12) reported that antibiotic therapy combined with computed tomography-guided percutaneous drainage was an acceptable alternative to nephrectomy. In this study, most patients received medical and percutaneous therapy. Only two patients required further nephrectomy.

To the best of our knowledge, only 14 cases in the literature describe bilateral EPN treated by medical therapy alone. The first case of bilateral EPN managed by medical treatment was reported by Naggapan

and Kletchko (13). Another such case recently was reported from our institution (14). Individual cases have been described in which a conservative approach involving good glycemic control, potent antibiotic coverage, and supportive treatment has been found successful (15–17). The two cases described here were managed with prompt imaging, rapid glycemic control, and potent antibiotics.

Certain factors have been associated with high mortality in EPN. Wan and Rullard (18) reported that thrombocytopenia, azotemia, and high urinary red blood cell counts are predictors of poor outcome in EPN. The severity of hematuria in patients with EPN probably reflects the degree of necrosis resulting from the infectious process and the presence of renal vein thrombosis. Altered consciousness, hypotension, severe proteinuria, and extension of infection to the perinephric space have also been associated with poor prognosis (11).

Thrombocytopenia, acute renal function impairment, altered consciousness, and shock can be the initial presentations of EPN, especially in severe cases. Clinicians should pay attention to these poor prognostic factors because patients exhibiting them may need more aggressive treatment and close monitoring. Despite having two factors each associated with adverse outcome (hypotension and azotemia in Case 1 and azotemia and thrombocytopenia in Case 2), both of the patients described here responded promptly and completely to early and aggressive medical treatment.

Clinical Pearls

- A poor response to antibiotic therapy in patients with diabetes thought to have uncomplicated pyelonephritis should raise the possibility of this life-threatening infection. In such cases, an early NCCT scan will clinch the diagnosis and help in planning the treatment.

- Early, aggressive medical treatment in the form of rapid control of blood glucose, administration of potent antibiotics, and provision of supportive treatment may avoid nephrectomy, and, in the case of bilateral disease, the need for lifelong renal replacement therapy.
- Thrombocytopenia, azotemia, high urinary red blood cell counts, altered consciousness, hypotension, severe proteinuria, and extension of infection to the perinephric space are predictors of poor outcome in EPN.

Duality of Interest

No potential conflicts of interest relevant to this article were reported.

References

1. Zargar AH, Wani AI, Masoodi SR, Laway BA, Bashir MI. Mortality in diabetes mellitus: data from a developing region of the world. *Diabetes Res Clin Pract* 1999;43:67–74
2. Smittherman K, Peacock JE. Infectious emergencies in patients with diabetes mellitus. *Med Clin North Am* 1995;79:53–57
3. Schaeffer AJ. Infections of the urinary tract. In *Campbell's Urology*. 8th ed. Walsh PC, Retik AB, Vaughan ED, Wein AJ, Campbell M, Eds. Philadelphia, Pa., Saunders, 2002, p. 556–558
4. Kelly HA, MacCallum WG. Pneumatocysturia. *JAMA* 1898;31:375–381
5. Schultz EH, Klorfein EH. Emphysematous pyelonephritis. *Urology* 1962;87:762–766
6. Zabbo A, Montie JL, Popowniak KL, Weinstein AJ. Bilateral emphysematous pyelonephritis. *Urology* 1985;25:293–296
7. Dunn SR, Dewolf WC, Gonzalez R. Emphysematous pyelonephritis: report of 3 cases treated by nephrectomy. *J Urol* 1975;114:348–350
8. Shigemura K, Yasufuku T, Yamashita M, Arakawa S, Fujisawa M. Bilateral emphysematous pyelonephritis cured by antibiotics alone: a case and literature review. *Jpn J Infect Dis* 2009;62:206–208
9. Huang JJ, Chen KW, Ruaan MK. Mixed acid fermentation of glucose as a mechanism of emphysematous urinary tract infection. *J Urol* 1991;146:148–151
10. Shokeir AA, El-Azab M, Mohsen T, El-Diasty T. Emphysematous pyelonephritis, a 15-year experience with 20 cases. *Urology* 1997;49:343–346

11. Huang JJ, Tseng CC. Emphysematous pyelonephritis clinicoradiological classification, management, prognosis, and pathogenesis. *Arch Intern Med* 2000;160:797–805
 12. Chen MT, Huang CN, Chou YH, Huang CH, Chiang CP, Lin GC. Percutaneous drainage in the treatment of emphysematous pyelonephritis: 10-year experience. *J Urol* 1997;157:1569–1573
 13. Naggapan R, Kletchko S. Bilateral emphysematous pyelonephritis resolving to medical therapy. *J Intern Med* 1992;232:77–80
 14. Kuchay MS, Laway BA, Bhat MA, Mir SA. Medical therapy alone can be sufficient for bilateral emphysematous pyelonephritis: report of a new case and review of previous experiences. *Int Urol Nephrol* 2014;46:223–227
 15. Grozel F, Berthezene Y, Guerin C, Tran-Minh VA, Croisille M. Bilateral emphysematous pyelonephritis resolving to medical therapy: demonstration by US and CT. *Eur Radiol* 1997;7:844–846
 16. Tahir H, Thomas G, Sheerin N, Bettington H, Pattison JM, Goldsmith DJ. Successful medical treatment of acute bilateral emphysematous pyelonephritis. *Am J Kidney Dis* 2000;36:1267–1270
 17. Sodgi M, Marih L, Nassib M, Himmich H. Bilateral emphysematous pyelonephritis cured by medical therapy alone. *Med Mal Infect* 2006;36:174–176
 18. Wan YL, Rullard MJ. Predictors of outcome in emphysematous pyelonephritis. *J Urol* 1998;159:369–373
-